Successful treatment with a modified Euro-Lupus induction regimen in pediatric lupus nephritis

Zanab Mian DO[1,2], Lydia Thomas MD[1,2], Vanesa Bijol MD[3], Joyce Hui Yuen MD MS[1,2], Heather Walters MD[1,2]
[1]Pediatric Rheumatology, Steven and Alexandra Cohen Children's Medical Center, Lake Success, NY
[2]Zucker School of Medicine at Hofstra/Northwell, Hempstead, NY
[3]Department of Pathology, Northshore University Hospital, Manhasset, NY
Contact: Heather Walters (hwalters@northwell.

Introduction

3-year-old male who presents with persistent fevers, vasculitic rash, and periorbital edema.

Case Presentation

History
- No significant past medical history
- Daily fevers for one month
- Rash along face and extremities over 2-3 months
- Review of Symptoms:
  - Positive: fevers, rash, constipation, decreased appetite, weight loss, periorbital and peripheral edema
  - Negative: fatigue, mouth sores, joint swelling, muscle weakness
- Physical Exam:
  - HEENT: Mild periorbital edema, no mouth sores
  - Skin: Malar rash, vasculitic lesions along ears and lower extremities with livedo reticularis pattern
  - MSK: bilateral knee arthritis

Renal Biopsy

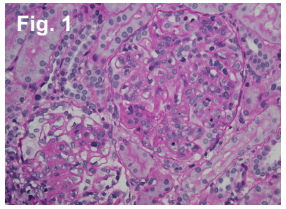

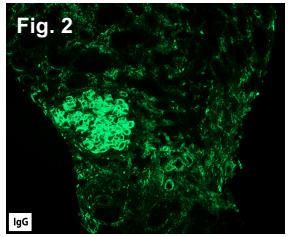

Diagnosis:
Class IV Lupus Nephritis
Diffuse global proliferative
NIH Activity Index 10/24
NIH Chronicity Index 0/12

Figure 1:
Light Microscopy showing endocapillary hypercellularity

Figure 2:
Immunofluorescence stain for IgG with deposition along mesangium and capillary wall; focal reactivity along interstitium and basement membrane

Electron Microscopy (not shown)
Mild foot process effacement, mesangial hypercellularity, with subendothelial deposits

Discussion

- In pediatric SLE, standard of care for induction therapy of proliferative lupus nephritis is either with IV cyclophosphamide or with MMF, plus the addition of glucocorticoid therapy.
- Although there have been randomized control trials for induction therapy in adult proliferative nephritis, there remains limited data in pediatric SLE regarding comparable outcomes between IV cyclophosphamide vs. MMF in lupus nephritis induction therapy.
- Observational cohort studies and case series have described aggressive treatment of pediatric Class III and Class IV disease using the NIH protocol, but limited number of pediatric patients have been monitored in terms of outcomes with the Euro-Lupus protocol.
- Evidence obtained in adult studies, like the Euro-Lupus Nephritis Trial (ELNT), suggest that patients with proliferative LN treated with low dose Euro-Lupus protocol achieved clinical results comparable to those treated with high dose NIH protocol.
- Extrapolating from this data led us to successfully treat our patient with a modified regimen to achieve clinical remission with a lower total cumulative dose.

Case Investigation

Table 1

Lab Test	Result	Ref Range
WBC	6.8	5-15.5 K/uL
Hgb	9.1	10-15 g/dL
Plt	338	150-400 K/uL
ESR	53	0-15 mm/hr
C3	13	81-157 mg/dL
C4	6	13-39 mg/dL
Urine Analysis	+600 protein	
UPC	20.5	0.0-0.2

ANA 1:2560
Anti-dsDNA >1000
Anti-Sm >8
Anti-RNP >8
Anti-Ro 3.3
Anti-La neg
aPLs neg
ANCAs neg

Special acknowledgements:
- Department of Pediatric Nephrology at Steven and Alexandra Cohen Children's Medical Center of NY

Case Management

Diagnosis: Systemic Lupus Erythematosus
Class IV Lupus Nephritis

- Steroid course: Methylprednisolone 30mg/kg/day for 3 days with subsequent transition to Prednisone 2mg/kg/day
- Patient received modified Euro-Lupus protocol:
  Cyclophosphamide 10mg/kg/dose every 2 weeks for 6 total doses
  = Cumulative dose of 1.2g
- Hypertension managed with daily Amlodipine and Enalapril BID

Table 2

Cytoxan (CYC)	UPC
Initial Visit	20.5
Dose 1	8.0
Dose 2	7.8
Dose 3	2.0
Dose 4	1.4
Dose 5	0.4
Dose 6	0.3
Follow-up	0.3

Patient Summary/Outcome

- Maintained on MMF (600mg/m2/dose) BID.
- Renal disease remains stable; continues to have mild-moderate microscopic hematuria at follow-ups with UPC ratio stable at 0.3
- Started Hydroxychloroquine (5mg/kg/day)
- Vasculitic rash recurred 2 months after last IV cyclophosphamide infusion, but resolved with addition of topical steroids and topical calcineurin inhibitor

Selected References

- Baskin, E, et al. *Pediatr Nephrol* 25, 111–117 (2010)
- Groot, N, et al. *Annals of the Rheumatic Diseases* 2017;76:1965-1973
- Houssiau, F.A, et al. *Arthritis & Rheumatism*, 46: 2121-2131
- Mina, R, et al. *Arthritis care & research* vol. 64,3 (2012): 375-83
- Szymanik, H, et al. *Central-European journal of immunology* vol. 41:3 (2016): 248-254